

# FOREIGN BODIES IN THE EXTERNAL AUDITORY CANAL

Written by Oh Chunghyeon

## **Background Information**

### **Definitions of levels of care (in this guideline)**

- Level 1: Community healthcare worker/non-doctor
- Level 2: Medical doctor
- Level 3: ENT Surgeon

One of the most common locations to find a foreign body (FB) is the external auditory canal (EAC) both in the paediatric and adult population<sup>1</sup>. If the FB becomes lodged in the bony cartilaginous junction the FBs can become impacted, increasing the difficulty of removal<sup>2</sup>. Consequences of otological FBs range from local irritation at insertion site, to serious complications such as tympanic membrane perforation and ossicular chain dislocation<sup>3</sup>.

### **Diagnosis**

History/Predisposing factors:

- Patients with otological FBs may be asymptomatic.
- A history of insertion may be reported by the child or the caregiver, but most often FB in the paediatric population are incidental findings<sup>4</sup>.

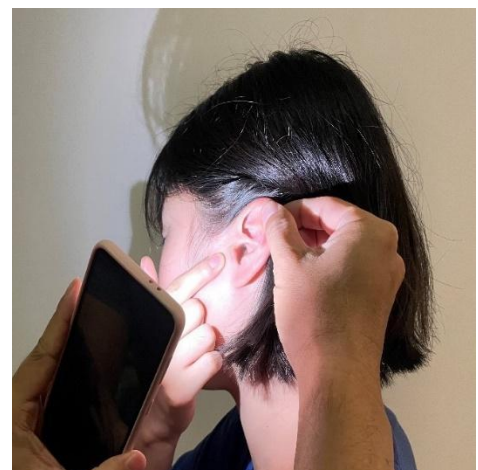
Symptoms:

- In some cases there are no symptoms
- Otagia
- Fullness
- Hearing impairment
- Discharge
- Delayed presentations in children are usually triggered by parents noticing blood-stained purulent discharge or bad smell<sup>3</sup>.

## **Examination and Investigations**

### **General:**

- Gently pull the pinna backward and upward to examine the EAC with a light source.
- To remove the FB without damage, you should consider its type and shape as well as its location, co-existing otological anomalies and the patient's level of cooperation.



### Level 1:

- Ask the patient to gently pull the tragus anteriorly with finger to open the EAC and at the same time the examiner should pull the pinna backward and upward.
- You may use any light source to examine the EAC (e.g.; \_\_\_\_\_ lantern, pen light, cellular phone light or sunlight).

### Level 2:

- Otoscopy should be performed with an otoscope.

### Level 3:

- Oto-microscopy or Oto-endoscopy should be performed.
- The choice of instrument for FB removal is according to the FB found (e.g.; alligator forceps, hook, cerumen removal loop).

## **Management**

### General:

- The first attempt at removal is critical because success rates decrease after the 1<sup>st</sup> failed attempt. Accordingly, complications increase as the number of failed removal attempts increases<sup>4</sup>.
- An uncooperative patient and the inability to safely sedate an uncooperative patient are contraindications to attempting FB removal<sup>5</sup>.
- Multiple FB are common, especially in children. Thus, all other orifices of the head should be inspected after removal of a FB from the EAC<sup>6</sup>.
- If live arthropods cause pain in the ear canal, the first step is to kill the arthropod allowing the patient to feel more comfortable and permit easier removal of the animal; multiple agents will accomplish this. Mineral oil and vegetable oil are recommended<sup>7,8</sup>.
- Certain types of foreign bodies, such as button batteries, require immediate emergent removal<sup>5</sup>.
- Hygroscopic inanimate FB, such as bean seed, peanuts and rice grain, need to be removed before swelling and impaction due to hydration in the ear canal.
- However, for most non-hygroscopic inanimate FB, such as beads, plastic, erasers, pater and stone, removal from the EAC is not emergent, although, in cases of prolonged retention of FB, significant oedema of the EAC may render removal more challenging and painful<sup>5</sup>.

### Level 1:

- Live insects: drown in vegetable or mineral oil. This will stop the buzzing and reduce pain.

### Level 2:

- Soft objects (e.g. cotton wool) can be removed with fine forceps and a headlight.
- Beads/round smooth solid objects: most are difficult to grab with forceps, which often push the object further in. A blunt right-angled hook allows the object to be pulled out from behind the object.
- Ear irrigation is recommended for small inorganic objects or insects.
- Specific methods might also be contraindicated in certain situations. For example, irrigation would be contraindicated with a suspected tympanic membrane perforation or removal of a battery.

- Irrigation may also be contraindicated in hygroscopic FB such as bean seed, peanuts, rice grain, and sponge materials. It may swell and enlarge if hydrated<sup>7</sup>.
- Refer to ENT as per local practices in the following circumstances: impossible to visualize FB, FB potentially penetrating the tympanic membrane, multiple failed attempts at removal, impacted FB in medial EAC, FB is next to the tympanic membrane<sup>3</sup>.

Level 3:

- Removal attempts are often painful, can cause bleeding that limits visualisation, and can further wedge the foreign body into the EAC.
- In patients that are uncooperative, high risk of tympanic membrane of middle ear damage, sedation or anaesthesia should be considered.

**Further reading**

1. Chiun, K. C., Tang, I. P., Tan, T. Y. & Jong, D. E. Y. H. Review of ear, nose and throat foreign bodies in Sarawak General Hospital. A five year experience. *Med J Malaysia* **67**, 17–20 (2012).
2. Heim, S. W. & Maughan, K. L. Foreign bodies in the ear, nose, and throat. *Am Fam Physician* **76**, 1185–1189 (2007).
3. Queensland, C. H. Foreign body in the ear – Emergency management in children | CHQ. *Children's Health Queensland*  
<https://www.childrens.health.qld.gov.au/guideline-foreign-body-in-ear-emergency-management-in-children/> (2019).
4. Schulze, S. L., Kerschner, J. & Beste, D. Pediatric external auditory canal foreign bodies: a review of 698 cases. *Otolaryngol Head Neck Surg* **127**, 73–78 (2002).
5. Lotterman, S. & Sohal, M. Ear Foreign Body Removal. in *StatPearls* (StatPearls Publishing, 2022).
6. Thompson, S. K., Wein, R. O. & Dutcher, P. O. External auditory canal foreign body removal: management practices and outcomes. *Laryngoscope* **113**, 1912–1915 (2003).
7. Leffler, S., Cheney, P. & Tandberg, D. Chemical immobilization and killing of intra-aural roaches: an in vitro comparative study. *Ann Emerg Med* **22**, 1795–1798 (1993).
8. World Health Organization. *Primary ear and hearing care training resource*.  
<https://apps.who.int/iris/handle/10665/43333> (2006).